

Acute temozolomide induced liver injury : Mixed type hepatocellular and cholestatic toxicity

Cem Aygun¹, Ayse Yıldırım Altınok², Aslı Çakır³, Ahmet Faruk Agan⁴, Yasemin Balaban⁵

(1) Department of Internal Medicine, Division of Gastroenterology, Istanbul Medipol University, Istanbul, Turkey ; (2) Department of Radiation Oncology, Istanbul Medipol University, Istanbul, Turkey ; (3) Department of Pathology, Istanbul Medipol University, Istanbul, Turkey ; (4) Department of Internal Medicine, Division of Gastroenterology, Istanbul Medipol University, Istanbul, Turkey ; (5) Department of Internal Medicine, Division of Gastroenterology, Istanbul Medipol University, Istanbul, Turkey

Abstract

Temozolomide (TMZ) is an oral imidazotetrazine methylating agent which is used for the treatment of glioblastoma multiforme (GBM). We report a case of acute hepatotoxicity in a 53-year old male patient after administration of TMZ for GBM. He had fatigue, nausea, anorexia and jaundice. His laboratory analysis showed alanine aminotransferase (ALT) : 632 IU/L (normal range 0-40) ; aspartate aminotransferase (AST) : 554 IU/L (normal range 5-34) ; alkaline phosphatase (ALP) : 1143 IU/L (normal range 40-150) ; γ -glutamyl transpeptidase (GGT) : 514 IU/L (normal range 9-64 IU/L) ; total bilirubin : 15.1 mg/dL (normal range 0-1.2) ; direct bilirubin : 13.2 mg/dL and prothrombin time (PT) : 13.5 s, with international normalized ratio (INR) : 1.1 (normal range 0.8-1.2). His liver biopsy specimen showed mixed-type (both hepatocellular and cholestatic) hepatic injury, compatible with a diagnosis of drug-induced hepatitis. An objective causality assessment using the Naranjo probability scale suggested that TMZ was the probable cause of the acute hepatitis. His liver function tests gradually normalized in 6 months after discontinuation of the drug. In susceptible individuals, TMZ use may lead to acute mixed type liver toxicity. Complete recovery may be possible if the drug is discontinued before severe liver injury is established. (*Acta gastroenterol. belg.*, 2016, 79, 487-489).

Key words : temozolomide, drug-induced cholestatic hepatitis.

Introduction

Malignant gliomas, one of the most common primary brain tumors, are very aggressive tumors with poor prognosis despite a multi-modality treatment approach including surgery, radiotherapy and chemotherapy. The median survival time of patients with glioblastoma multiforme (GBM) is only 5-12 months from the diagnosis. Unfortunately, the standard chemotherapy of nitrosoureas or procarbazine-based regimens has only modest activity and significant toxicity when used in the setting of recurrent malignant gliomas. Therefore, there is considerable interest in new chemotherapy agents such as temozolomide (TMZ). TMZ is an imidazotetrazine derivative of the alkylating agent dacarbazine. It undergoes rapid chemical conversion in the systemic circulation at physiological pH to the active compound, 5-(3-methyltriazene-1-yl) imidazole-4-carboxamide (MTIC). TMZ exhibits schedule-dependent antineoplastic activity by interfering with DNA replication. The therapeutic benefit of TMZ depends on its ability to alkylate/methylate DNA, which most often occurs at the N-7 or O-6 positions of guanine residues.

This methylation damages the DNA and triggers the death of tumor cells. The most common adverse effects associated with TMZ are hematologic ones like bone marrow suppression but non-hematologic side effects such as somnolence, headache, dermatitis, nausea and vomiting can be seen as well (1,2).

Liver injury after TMZ use is rare. Underreporting may be a contributing factor to the absence of reports of hepatotoxicity of TMZ. The severity of injury may vary from minor non-specific changes in hepatic structure and function to fulminant hepatic failure. The term drug-induced liver disease should be confined to cases in which the nature of the liver injury has been characterized histologically, because biochemical parameters used to detect liver injury may also be elevated as an adaptive response to drugs (2). In this case report we aimed to report a biopsy-confirmed TMZ induced acute cholestatic hepatitis and to focus on the problems of TMZ induced hepatotoxicity.

Case report

A 53-year-old man was admitted to hospital for nausea, vomiting, red-itchy skin, jaundice and asthenia. His medical history included biopsy-proven inoperable pontine GBM treated with radiotherapy and adjuvant TMZ. A six-week course of TMZ (75 mg/m²/day) with radiotherapy was given initially. Four weeks after completion of this treatment, TMZ (200mg/m²/day) once daily for 5 days, out of each 28 day cycle, was prescribed. Three weeks after the first attempt of this second treatment period, patient had fatigue, nausea, vomiting, anorexia, red-itchy skin and jaundice. Emergency laboratory analysis showed the following results : Alanine aminotransferase (ALT) : 632 IU/L (normal range 0-40) ; aspartate aminotransferase (AST) : 554 IU/L (normal range 5-34) ; alkaline phosphatase

Correspondence to : Cem Aygun, Istanbul Medipol University, Department of Internal Medicine, Division of Gastroenterology, Istanbul, Turkey
E-mail : caygun1@yahoo.com

Submission date : 21/06/2015
Acceptance date : 03/08/2015

(ALP) : 1143 IU/L (normal range 40-150) ; γ -glutamyl transpeptidase (GGT) : 514 IU/L (normal range 9-64 IU/L) ; total bilirubin : 15.1 mg/dL (normal range 0-1.2) ; direct bilirubin : 13.2 mg/dL and prothrombin time (PT) : 13.5 s, with international normalized ratio (INR) : 1.1(normal range 0.8-1.2). Blood tests for glucose, blood urea nitrogen (BUN), serum creatinine, total protein, albumin, uric acid, total cholesterol and triglycerides were within normal limits. There was no peripheral eosinophilia. The patient was hospitalized and TMZ treatment was discontinued. Additional test results for hepatitis A, B, C and E viruses, cytomegalovirus, and Epstein-Barr virus were negative. Ferritin and seruloplasmin levels were within normal limits. Autoantibodies (antinuclear, antimitochondrial, anti-smooth-muscle, anti-liver-kidney microsomal enzymes and anti-soluble liver antigen) were also negative. Hepatobiliary imaging with ultrasonography was normal other than mild hepatosteatosis. He denied taking any other medications or using alcohol or any herbal or folk remedies at any time. There were no known contributing environmental issues. One week after hospitalization, his liver function tests were as follows : ALT, 532 IU/L ; AST, 434 IU/L ; ALP, 1064 IU/L ; GGT, 486 IU/L ; total bilirubin, 13.99 mg/dL ; and direct bilirubin, 12.4 mg/dL. Both his medical history and laboratory results suggested severe acute hepatitis of mixed-type, with hepatocellular and cholestatic hepatic injury, and liver biopsy was performed. The histopathological samples revealed centrilobular and portal cholestatic hepatitis, without fibrosis or necrosis, highly suggestive of drug-related hepatotoxicity (Figures 1,2). Within 2 weeks of hospitalization, the patient had significant subjective improvement, and showed improvement of liver function tests (ALT, 107 IU/L ; AST, 103 IU/L ; ALP, 945 IU/L ; GGT, 333 IU/L ; total bilirubin, 11.8 mg/dL ; and direct bilirubin, 10.26 mg/dL). After 8-week follow up, his liver function test results were mostly within normal limits (ALT, 19 IU/L ; AST, 18 IU/L ; and total bilirubin, 1.19 mg/dL). The patient was discharged in good condition. The probability that the symptoms of hepatotoxicity that occurred after TMZ treatment were an adverse drug reaction (ADR) was assessed using the Naranjo ADR probability scale. The total Naranjo score for the patient was 7, which is in the "probable" range (3).

Discussion

Fourteen weeks after the start of treatment with TMZ, our 53-year-old male patient experienced signs of hepatotoxicity with itchy-red skin, jaundice, nausea, vomiting and asthenia. Laboratory testing showed marked elevations in serum ALT, AST, ALP, GGT and total bilirubin concentrations. His symptoms, as well as the liver tests, resolved on discontinuation of the drug treatment. The subtype of the hepatotoxicity observed in the patient was considered as mixed hepatocellular

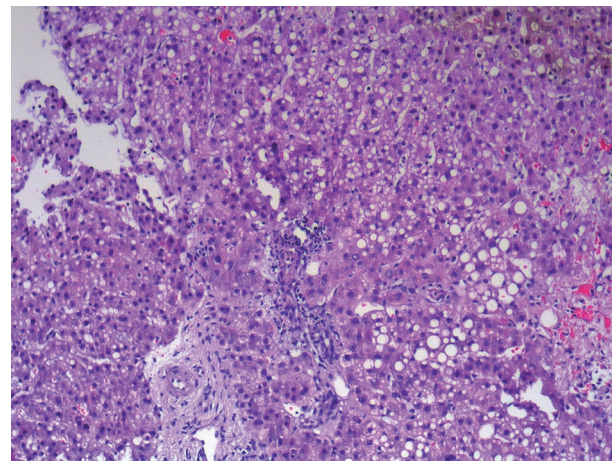


Fig. 1. — Liver biopsy specimen showing cholestasis, steatosis, and portal inflammation, (HEX100).

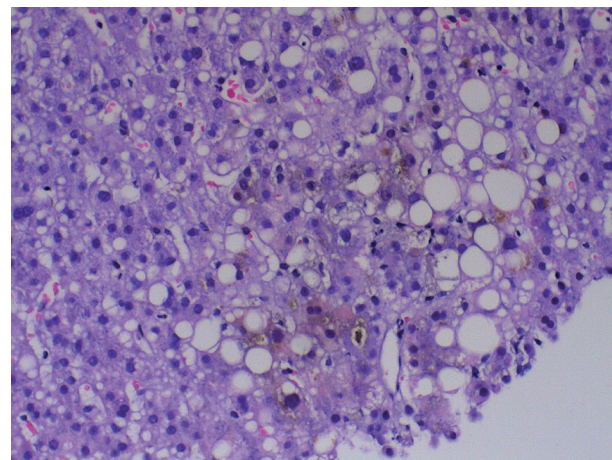


Fig. 2. — Canalicular cholestasis and focal necrosis with steatosis, (HEX200).

and cholestatic. The diagnosis of severe TMZ-induced hepatotoxicity in our case was suggested by : (1) symptoms such as fatigue, nausea, vomiting, anorexia, and jaundice several weeks after TMZ initiation ; (2) the chronology between TMZ introduction and liver test abnormalities ; (3) histological findings that were highly suggestive of a toxic mechanism ; (4) absence of any other clear etiology ; and (5) recovery after TMZ withdrawal.

Because the presenting features, clinical course, and outcomes of TMZ hepatotoxicity have not been well defined yet, the aim of this report was to describe the clinical, biochemical and histological features of our patient with apparent hepatotoxicity due to TMZ. Cholestasis with hepatitis is a frequent type of hepatic drug reaction and it is characterized by conspicuous cholestasis with hepatocellular injury. Histological lesions may show lobular and portal tract inflammation, often with neutrophils, eosinophils or mononuclear cells (4). The clinical spectrum of cholestatic hepatitis

was indicated in our case by itching and jaundice. It was also reflected by the markedly elevated liver tests, with increased serum bilirubin, GGT and ALP. Cases of mixed cholestasis and hepatitis are considered highly suggestive of a drug reaction (5).

Clinically, to exclude dilation of large bile ducts produced by biliary obstruction, and hepatic or pancreatic masses, hepatobiliary imaging is essential. Ultrasound is the most preferred method to rule out possible bile duct obstruction. Computed tomography (CT), magnetic resonance cholangio-pancreatography (MRCP), endoscopic retrograde cholangio-pancreatography (ERCP), percutaneous transhepatic cholangiography (PTC) may be necessary in difficult cases. In the absence of the symptoms mentioned earlier with apparent clinical findings, drug-induced cholestasis is more likely, and a liver biopsy is often advisable. Certain histological findings, such as lobular and portal tract inflammation, suggest a hepatic drug reaction, whereas others such as edema of the portal tracts suggest biliary obstruction. When the temporal relationship to drug ingestion indicates a high probability of a drug reaction, particularly when the agent is known to be potentially hepatotoxic, it is appropriate to discontinue the incriminated drug and observe whether improvement occurs. Recovery may be seen rapidly if the drug is discontinued before severe liver injury is established (6).

Hepatocytes, because of their capability to metabolize drugs, form minute amounts of drug-protein adducts, for which the immune system normally shows tolerance. Hypersensitivity reactions occur when this tolerance is impaired. Additional signals, such as a concomitant inflammatory reaction, may eventually be needed to break this tolerance. The allergic hepatitis induced by drugs is generally a type IV hypersensitivity reaction involving CD4+, CD8+ cytotoxic lymphocytes, as well as natural killer cells. Antibodies directed to the drugs are much less common. Antibodies against cellular components may, however, occur when the sensitization process evolves towards an autoimmune reaction (7,8). In our patient, autoantibodies were negative which was consistent with a metabolic type of idiosyncratic toxicity.

The lack of hepatic metabolism may explain why TMZ hepatotoxicity is an infrequent event. Dacarbazine and mitozolomide are the other two most closely related alkylating agents of the imidazotetrazine family. Dacarbazine is a well-known hepatotoxin, but the pattern of injury is sinusoidal obstruction syndrome (veno-occlusive disease) rather than hepatitis or cholestasis. Both dacarbazine and mitozolomide, like TMZ, cause varying degrees of bone marrow suppression. This led to the abandonment of mitozolomide after phase II clinical trials showed that it caused severe and unpredictable myelosuppression (9,10).

In summary, with this report, we presented a case of hepatotoxicity after fourteen weeks of TMZ treatment for GBM. The toxicity appeared to be associated with drug use. Although rare, mixed-type (hepatocellular and cholestatic) hepatic injury might be associated with TMZ use in some cases. Patients may present with fatigue, nausea, vomiting, anorexia, pruritis and jaundice. Complete recovery may be possible if the drug is discontinued before critical liver injury is established.

References

1. GRANT L.M., KLEINER D.E. *et al.* Clinical and histological features of idiosyncratic acute liver injury caused by temozolomide. *Dig. Dis. Sci.*, 2013, **58** : 1415-21.
2. YANG S.H., KIM M.K. *et al.* Temozolomide chemotherapy in patients with recurrent malignant gliomas. *J. Korean Med. Sci.*, 2006, **21** : 739-44.
3. Naranjo C.A., Busto U. *et al.* A method for estimating the probability of adverse drug reactions. *Clin. Pharmacol. Ther.*, 1981, **30** : 239-245.
4. LEE W.M. Drug-induced hepatotoxicity. *N. Engl. J. Med.*, 2003, **349** : 474-485.
5. FARREL G.C. Liver disease caused by drugs, anesthetics and toxins. In : Mark Feldman, Lawrence S Friedman, Marvin H., editors. *Sleisenger and Fordtran's gastrointestinal and liver disease : pathophysiology, diagnosis, management*. 7th ed. Philadelphia : *Saunders*, 2002 : 1403-1437.
6. CHITTURI S., FARRELL G.C. Drug-Induced Liver Disease. *Curr. Treat. Options Gastroenterol.*, 2000, **3** : 457-462.
7. PICHLER W.J. Delayed drug hypersensitivity reactions. *Ann. Intern. Med.*, 2003, **139** : 683-693.
8. DEPTA J.P., PICHLER W.J. Cross-reactivity with drugs at the T cell level. *Curr. Opin. Allergy Clin. Immunol.*, 2003, **3** : 261-267.
9. ERICHSEN C., JONSSON P.E. Veno-occlusive liver disease after dacarbazine therapy (DTIC) for melanoma. *J. Surg. Oncol.*, 1984, **27** : 268-270.
10. FAIRBAIRN L.J., CHINNASAMY N. *et al.* Enhancing hemopoietic drug resistance : a rationale for reconsidering the clinical use of mitozolomide. *Cancer Gene. Ther.*, 2000, **7** : 233-239.